

Breast Carcinoma Associated with A Supernumerary Breast

Christopher Bierton^{1*}, MBBS, MSc, FRACS; Associate Professor Beverley Fosh², MBChB, BSc(Hons), MD, FRACS

¹General Surgery, Modbury Hospital, Adelaide, South Australia, Australia

²Adelaide University, South Australia, Australia

*Corresponding author: Christopher Bierton, Email: christopher.bierton@sa.gov.au

Citation: Bierton C, Fosh B (2026) Breast Carcinoma Associated with A Supernumerary Breast. Annal Cas Rep Rev: ACRR-458.

Received Date: 19 February, 2026; Accepted Date: 23 February, 2026; Published Date: 27 February, 2026

Abstract

Aberrant breast tissue occurs in an estimated 6% of the population, carrying with it its own risk of breast cancer. Whilst rare, this constitutes 0.3% of breast cancer cases and due to the atypical nature of presentation they are often more advanced and associated with a worse prognosis. This case report describes the clinical presentation of a young woman with such a diagnosis and her clinical journey.

Introduction

Aberrant breast tissue may occur anywhere along the mammary ridge in up to 6% of the population and be classified using the Kajava classification depending on the various combinations of presence or absence of nipple, areola, glandular tissue or hair [1]. Within this tissue originates 0.3% of all breast cancer cases, with the majority occurring from ectopic breast tissue situated in the axilla [2]. Investigation, staging and management should be performed in the standard manner as for carcinoma arising in orthotopic breast tissue [3] although no set guidelines are in place given the rarity of the condition.

Case report

A 34-year-old female was referred to the Breast Surgery Outpatient Department with an increasingly palpable mass adjacent to her right accessory nipple and a fine needle

aspiration (FNA) organised by her General Practitioner showing an atypical proliferative epithelial lesion concerning for malignancy.

She stated that she had noted a small lump adjacent to her known right, inframammary accessory nipple for a few years, however within the last year it had become increasingly firm. There was no local skin change, and it was occasionally tender. There was no discharge from the accessory nipple and there had been no changes to either of her orthotopic breasts. She had no personal or family history of breast cancer.

On examination there was a small 10x5mm firm, partially mobile mass immediately lateral to her accessory nipple. There was a palpably enlarged lymph node in the right axilla 2cm in size; the patient stated that it only appeared after her initial biopsy. Bilateral orthotopic breast exam was unremarkable.

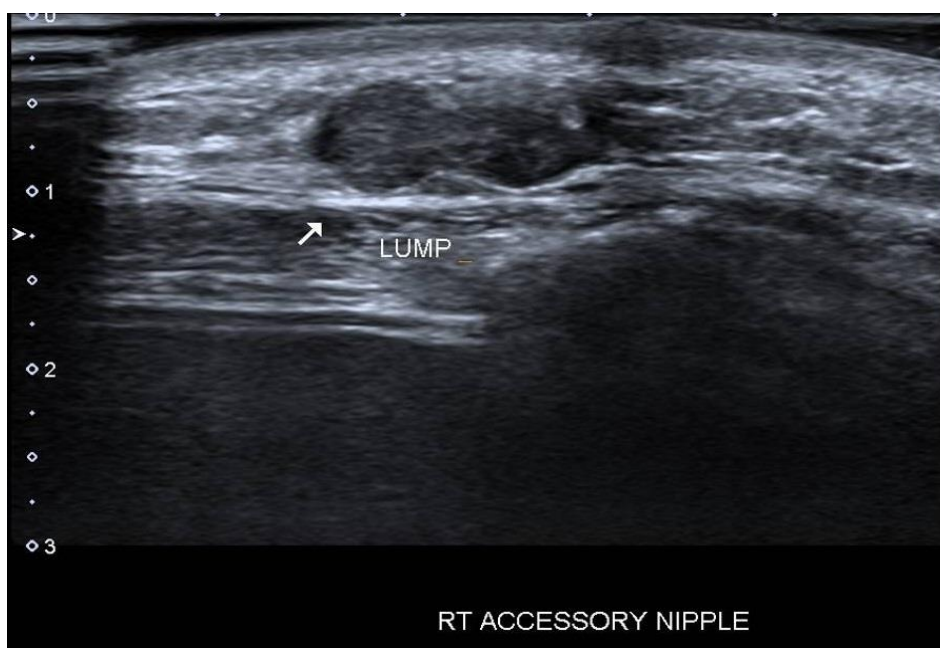


Figure 1: Ultrasound scan of palpable lump adjacent to accessory nipple.

Bilateral mammogram and tomosynthesis revealed no concerning features, however the accessory nipple was not seen well. Ultrasound showed a heterogenous mass immediately deep and lateral to the accessory nipple, initially 11x5x7mm in size.

The axillary lymph node appeared reactive. There were multiple sub-centimetre simple cysts within the right orthotopic breast. FNA of the axillary node showed only normal lymphoid tissue.

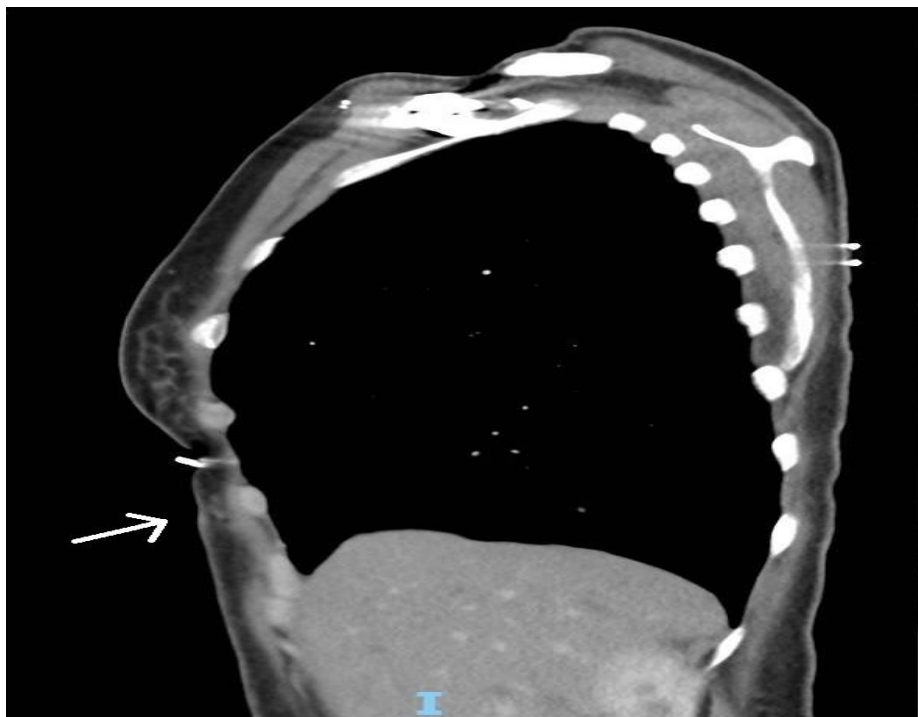


Figure 2: CT scan (sagittal) showing supernumerary breast tissue within subcutaneous tissue (arrow) inferior to orthotopic breast.

A wide local excision of the accessory nipple and adjacent mass was performed as the location made core biopsy technically difficult. The histopathology results returned as a grade 3 invasive ductal carcinoma that was oestrogen-receptor (ER) positive, progesterone-receptor (PR) positive and HER2 positive; triple positive with associated high-grade ductal carcinoma in-situ. There were positive resection margins for both invasive and non-invasive disease.

She underwent further imaging including Magnetic Resonance Imaging (MRI) breasts, staging Computed-Tomography (CT) and Bone Scintigraphy that revealed no evidence of disease in her orthotopic breasts or any metastatic disease. She proceeded to have a re-excision of margins, sentinel lymph node biopsy and infusaport insertion. Histopathology showed no residual cancer within the re-excision but 1 of 3 sentinel lymph nodes positive with a macrometastasis with focal extracapsular extension. She proceeded to a level 2 axillary clearance with a further 15 negative lymph nodes.

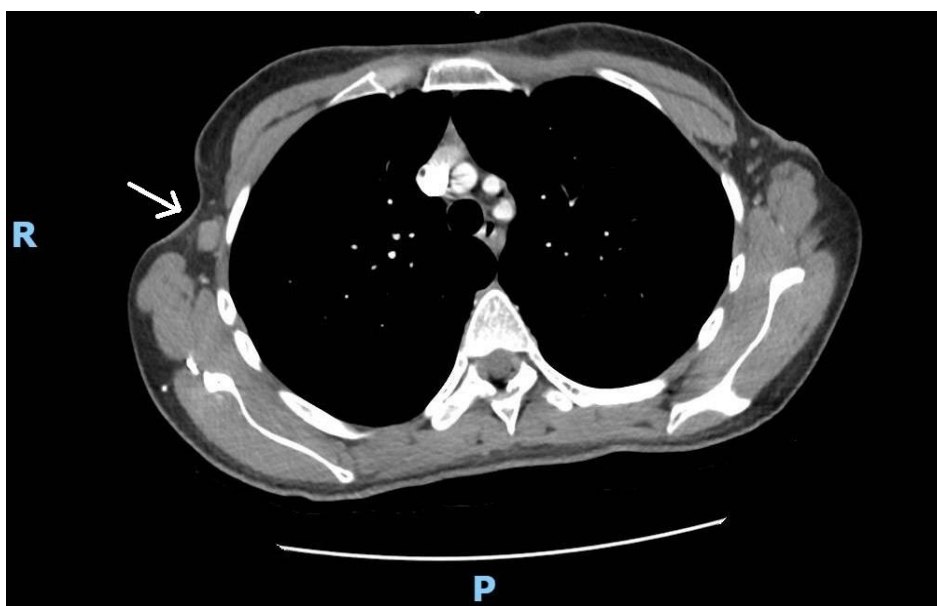

Figure 3: CT scan (axial) showing an enlarged lymph node.

Her case was discussed at a multidisciplinary team meeting, and she progressed to having adjuvant chemotherapy, radiotherapy, trastuzumab and endocrine therapy.

Discussion

Given their atypical presentation and potential lack of appropriate screening, breast cancer occurring within ectopic tissue is generally more advanced with poorer outcomes [5]. Our patient fortunately only had locoregional disease at time of diagnosis. This may have been aided by the minimal amount of ectopic breast tissue associated with her accessory nipple, making the clinical change more apparent earlier in its course.

Breast cancer screening of ectopic breast tissue should be performed at the same time as orthotopic breast tissue. Screening will often utilise standard imaging such as mammogram, ultrasound or MRI depending on the anatomical position of the tissue, but this must be prompted by either the patient or clinician correctly identifying the presence of aberrant tissue as well being aware of the potential risk associated with it. An excellent example of this is reported by Sperduto et al. [4] in which a woman with BRCA-1 mutation experienced breast cancer in a supernumerary breast after prophylactic excision of her orthotopic breasts and subsequently had multiple supernumerary breasts excised. This shows the importance of a full examination and recognition of accessory breast tissue or nipples when performing risk-reducing surgery to include these in the excision planning, and considering resection of aberrant tissue in the case of a primary breast cancer operation on the orthotopic breast. In our case the patient was too young to be

enrolled in routine screening anyhow and therefore had to rely on symptoms prior to diagnosis.

Conclusion

This case represents a rare presentation of breast cancer in a young woman based on her presentation with clinical signs and symptoms. Standard management according to general guidelines should be followed including adjuvant therapies, especially in younger cohorts.

Disclosure Statement

Signed consent from the patient involved has been obtained. There are no declarations of conflict of interest.

References

1. Surcel E, Koljonen C. 2023. Kajava Classification: The Person and the Research. *Aesth Plast Surg.* 47:2177-2178.
2. Gueye L, Thiam M, Gueye S, et al. 2019. Infiltrating tubular-papillary carcinoma of supernumerary left breast: A case report. *J Case Rep Images Obstet Gynecol.* 5.
3. Youn H, Jung S. 2009. Accessory Breast Carcinoma. *Breast Care.* 4:104-106.
4. Sperduto W, McCullough A, Northfelt D, et al. 2023. Implications of a supernumerary nipple breast cancer in a breast cancer sequence variation carrier: a case report. *Mayo Clin Pro Innov Qual Outcomes.* 7(5):437-442.
5. Bui A, Oyeniyi J, Loving B, et al. 2025. Management of low-grade ductal carcinoma in situ in a supernumerary breast: A case report. *Cureus.* 17(10):e94169.