

OEIS Complex: A Case Report and Literature Review of a Rare Polymalformative Syndrome

Aurore Albane Essomba*, Kamsu Zicfried, Jeannette Euranie Kouam, Marguerite Edongue, Sophie Nzotsa, Michèle Natacha Engama, Daniel Armand Kago, Evelyn Mah

Faculty of Medicine and Biomedical Sciences, The University of Yaoundé 1, Yaoundé, Cameroon.

*Corresponding authors: Aurore Albane Essomba, Faculty of Medicine and Biomedical Sciences, The University of Yaoundé 1, Yaoundé, Cameroon. Email: kamsuzicfried@yahoo.fr, aurore.albane@gmail.com

Citation: Essomba AA, zicfried K, Kouam JE, Edongue M, Nzotsa S, et al. (2022) OEIS Complex: A Case Report and Literature Review of a Rare Polymalformative Syndrome. In Arch Pedia Neon: IAPN-115.

Received Date: April 05th, 2022; **Accepted Date:** May 09th, 2022; **Published Date:** May 14th, 2022

Abstract

Introduction: The OEIS complex or syndrome is the most severe form of the exstrophy-epispadias complex and is characterized by the existence of an omphalocele, bladder exstrophy, anal imperforation and spina bifida. We report an atypical case of OEIS complex associated with further birth defects admitted to our department. The diagnostic and therapeutic approach to the complex congenital malformations involved are highlighted, as well as difficulties encountered in a limited resource setting.

Case Report: This was a neonate referred for the management of a congenital malformation on the first day of life. The baby was born vaginally at 35 weeks of gestation with a birth weight of 2000g and significant major risk factors for neonatal sepsis. Two antenatal ultrasounds had revealed fetal uropathy. On admission, the clinical exam revealed: a type 1 omphalocele, an anorectal malformation with a recto-urinary fistula and a covered lumbosacral dysraphism. Paraclinical examinations revealed an associated cardiac anomaly. The karyotype analysis was not done due to lack of financial means. Supportive care was given and the neonate underwent surgical reconstruction of birth defects on day 20.

Conclusion: The OEIS complex is a rare morbid congenital polymalformative syndrome in neonates. Patients require keen diagnostic enquiry and immediate postnatal multidisciplinary management, with long-term follow-up.

Keywords: OEIS complex, cloacal exstrophy, congenital malformation.

Introduction

Cloacal exstrophy is an extremely rare congenital anomaly (1/200000 to 1/400000 live births) related to abnormal development of the cloacal membrane, which is a transitional membrane composed of endoderm and ectoderm that covers the embryonic cloacae [1]. The arrest of the development of the cloacal membrane leads to the externalization of the urethra, vagina and rectum through a common orifice. Defective embryogenesis exacerbates the problem by disrupting the continuity of the abdominal wall, resulting in an abdominal wall defect with failure of closure of the lower urinary tract, the colon and other possible developmental anomalies [1,2]. This major congenital anomaly is the most severe form of the bladder exstrophy-epispadias complex spectrum characterized by omphalocele, bladder exstrophy, anal imperforation and spinal defects grouped under the term OEIS complexe [3,4]. It is often associated with other malformations, involving the gastrointestinal and skeletal spheres [3]. It was first described in 1709 by LITTRE, and for a long time was considered a devastating pathology due to infectious,

metabolic or nutritional complications associated with short bowel syndrome and intestinal obstructions [2, 5]. Nowadays, advances in neonatal resuscitation and the development of new surgical practices justify a survival rate of 83-100% [6]. However, the prognosis, although dependent of associated anomalies, remains uncertain in our context with a low technical platform. We report a clinical case of an OEIS complex admitted to our department. The complexity of the congenital malformations and the therapeutic difficulties are highlighted.

Case presentation

This is a newborn baby on its first day of life referred for the management of a congenital malformation noted at birth. The mother was primiparous, aged 22 years, the father was 26 years old with no notion of consanguinity. Four prenatal consultations (PCN) had been carried out in a rural area with an undocumented infectious work-up. We did not find any consumption of teratogenic substances such as alcohol, traditional pharmacopoeia products or others. There was no history of high blood pressure, gestational diabetes or any

other chronic pathology during pregnancy, fasting blood glucose was at 0.82g/l. The mother had received iron and folic acid throughout the pregnancy in adequate doses. Two ultrasound scans were performed, the last one at 33 weeks' gestation, which showed pyelocal dilatation of the right kidney in favor of a fetal uropathy. Delivery was per vaginal at 35 weeks' gestation + 3 days, with amniotic fluid described as meconium stained and fetid. The birth weight was 2000 g with an Apgar score of 8 and 10 at the 1st and 5th minute respectively.

Physical examination on admission revealed: a pink, quadriflexed newborn with normal vital and anthropometric parameters for gestational age. Signs of prematurity including thin skin and lanugo were found.

Upon physical exam, the estimated gestational age was equivalent to 36 weeks according to the Ballard score. The neurological examination was normal. We had a type 1 omphalocele with an umbilical hernia marked by a soft, painless, expansive and poorly reducible swelling, largely covered by the skin, centered on the umbilicus with a neck of about 3 cm in diameter and height (fig1). The newborn also had cloacal exstrophy with two exstrophied hemi bladders, separated by the everted cecum with meconium discharge mixed with urine (fig1). There was a sexual differentiation anomaly, anorectal malformation with recto-urinary fistula (fig1). On the other hand, there was a covered lumbosacral dysraphism, we had no deformity of the limbs or joints (figure 2).

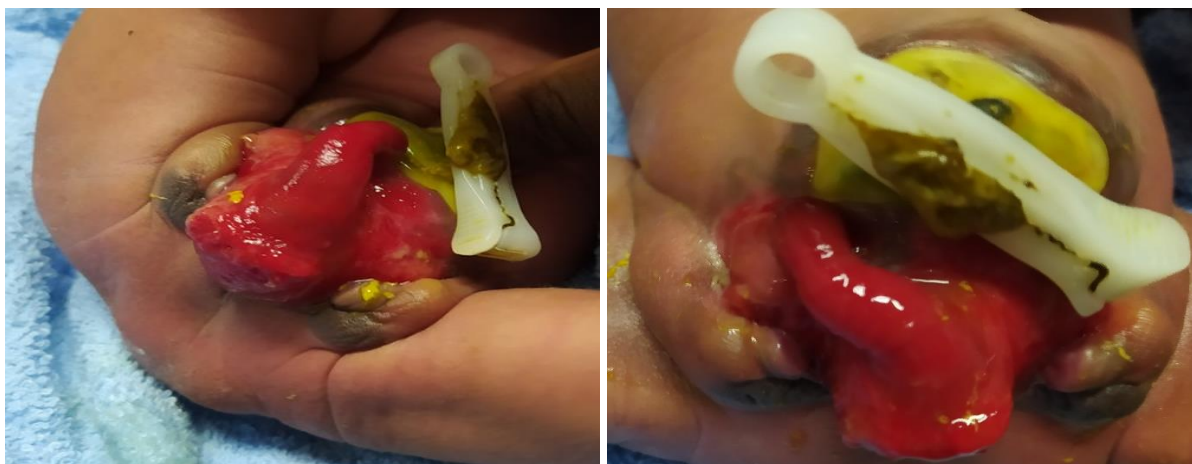


Figure 1 and 2: omphalocele type 1, cloacal exstrophy, anal imperforation, external genitalia ambiguity.

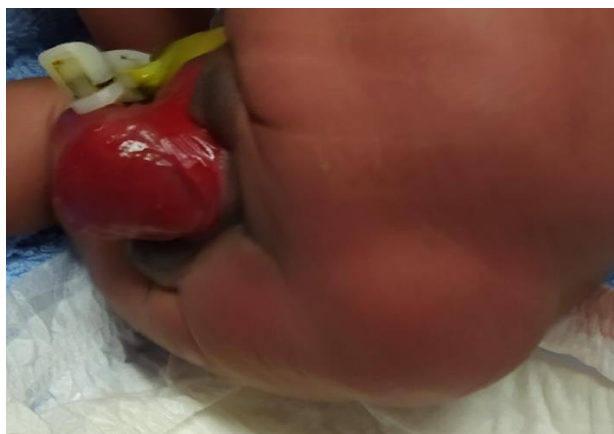

Figure 3: spina bifida occulta meningocele.

Medical imaging examinations were carried out to determine the nature and extent of the malformations. Cardiac ultrasound revealed an ostium secundum type inter-atrial communication of approximately 2.5 cm, the interventricular septum being intact (fig4). Abdominal and pelvic ultrasound concluded there was bladder exstrophy, with integrity of the intra-abdominal organs. The transfontanelar ultrasound showed a posterior superficial formation of pure anechoic content measuring 38 x 17 x 33 mm, that is 11 cc in volume, with an opening into the medullary canal, suggesting a meningocele, the dural sheath not being visualized in the mass. Moreover, the requested

karyotype could not be performed due to lack of financial means.

The newborn was put on triple antibiotic therapy (cefotaxime, ampicillin and gentamycin) in view of the meconium-stained and fetid coloration of the amniotic fluid for 10 days according to the department's protocol. Enteral feeding with breast milk was started on the second day of hospitalization due to the absence of secretions coming back through the nasogastric tube. Twice daily wet dressings of the abdomen were performed until the surgery.

The child underwent surgery on the 20th day of life. This consisted of a two-step surgical intervention, of which the first comprised an exploratory laparotomy with a peri

omphalocele incision and the reconstruction of digestive and uro-genital defects. The second step consisted of lumbosacral dysraphism menongoccele repair.

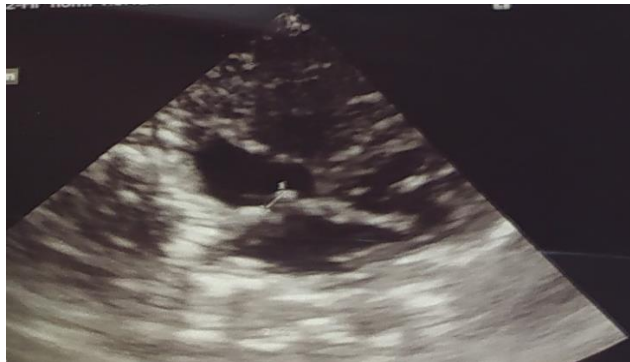

Figure 4: Ostium secundum type atrial septal defect of about 2.5 cm.

Discussion

The OEIS complex constitutes a spectrum of anomalies whose definition has long been controversial due to the variety of clinical presentations. These have been grouped under the acronym OEIS: Omphalocele, exstrophy, anal imperforation and spinal defect [7]. Cloacal exstrophy, which we report, is the most severe and rare of the four clinical forms of the OEIS complex. It was first described in 1709 by Littré, and more than two centuries later, the first successful surgical repair was introduced in 1812 by Meckel [8].

The incidence of cloacal exstrophy is approximately 1/200,000-400,000 live births although some authors suggest a higher incidence, hidden by undiagnosed or misdiagnosed forms [9]. A male predominance has been reported but more recent studies rule out a gender predilection [10,11].

Numerous risk factors, specifically teratogenic factors (diphenylhydantoin, diazepam, methamphetamine, valproic acid), assisted reproduction, alcoholism, smoking, diabetes mellitus, multiparity, influenza and gonococcal infections have been reported to increase the risk of cloacal exstrophy [12, 13]. However, most of these associations were limited to one or two cases [14]. Thus, there is very little evidence for a causal link between specific teratogenic factors and cloacal exstrophy.

Cloacal exstrophy is more common in monozygotic twins than in heterozygotic twins suggesting a genetic component to the syndrome [14]; it may also be associated with trisomy 21, trisomy 18, Triple-X syndrome, Turner syndrome and 1p36 deletion [7,14]. A potential cause could be mutations in the HLXB9 and HOX genes, the so-called homeobox genes involved in embryonic mesoderm development [15].

In our case, due to financial limitations of the patient's family, maternal infectious workup was not performed, neither were genetic investigations. Nevertheless, the early maternal age found in our case, just as the notions of fetid and meconium stained amniotic fluid as infection criteria, were non negligible risk factors for congenital malformations [12, 16, 17, 18].

Several possible embryological mechanisms have been raised concerning the OEIS syndrome, including a defect in blastogenesis where there is a single defect localized in the early caudal mesoderm at about 29 days of development, or a lack of mesodermal migration during the early period of striation. Indeed, failure of cloacal septation with persistence of the cloaca, rudimentary midgut and imperforate anus may occur. As well as failure of cloacal membrane breakdown resulting in cloacal exstrophy, omphalocele, lack of pubic rami fusion and also abnormal vertebrae resulting from somite malformation [4, 9].

According to Mallikarjunappa et al, antenatal diagnosis is possible in the second trimester of pregnancy by identifying syndromic components. These are classified into major criteria such as: non-visualization of the bladder, omphalocele, myelomeningocele, subumbilical abdominal lesion. While minor criteria comprise: malformations of the locomotor system, kidneys, hydrops fetalis, hydrocephalus, single umbilical artery [13-22]. In our case, only malformative uropathy was suspected during the antenatal period, proving the diagnostic limitations of ultrasound in these cases.

According to the authors, fetal MRI represents the gold-standard for prenatal diagnosis of OEIS complex. Indeed, it allows a better visualization of the structures and defects that may be present, but is not always accessible in current practice [9,18-25]. Antenatal diagnosis offers several advantages, such as a better understanding of the condition by the parents with psychological, financial and moral preparation for treatment as well as in utero transfer to facilities able to manage cloacal exstrophy. This makes perinatal and maternity accommodations feasible for the mother and the baby [9,26-36].

The clinical diagnosis of cloacal exstrophy may be obvious at birth. However, in this patient, its four classical components were contested with spina bifida occulta of lumbosacral location. Classical cloacal exstrophy manifests as two exstrophied bladder halves divided by a band of exstrophied cecum, usually accompanied by a prolapsed ileal segment. In our case, there was no typical small bowel prolapse, the so-called "elephant trunk" deformity. It is common to find duplicated appendicular orifices in the central band. The

most inferior orifice, representing the distal colon, was not duplicated in this newborn. It is not always obvious on inspection to distinguish the various digestive segments, and the true intestinal anatomy in all cases is only established on surgical exploration (Fig. 2). The male genitalia are usually represented as an epispadias penis on the widely separated pubic bones. In female fetuses, the mullerian duct orifices may be exstrophied under the bladder mucosa, a double vagina and a bifid clitoris may be present. In our case, it was difficult to determine the sex of the newborn from external examination.

Surgical correction of cloacal exstrophy is usually initiated in the neonatal period, within the first 72 h of life if possible [7]. Multidisciplinary collaboration is essential for comprehensive and effective management, involving neonatal pediatricians, pediatric surgeons and urologists. It is also recommended that neurosurgeons be consulted in the management of spinal dysraphism [7].

Pediatric management, including preoperative resuscitation, is the cornerstone [22]. Indeed, correction can only take place once the patient is medically stable. Early correction reduces bacterial colonization of exposed viscera and may reduce the need for pelvic osteotomy. An individualized approach to reconstruction of the genitourinary and gastrointestinal tract, whether in one or more stages, is commonly recognized as producing the best long-term outcome. According to several authors, the goals of repair include safe closure of the abdominal wall and bladder, preservation of renal function, prevention of bowel syndromes, functional and cosmetic reconstruction of the genitalia, and achievement of acceptable urinary and fecal continence [7, 9, 13, 20, 21].

From a pediatric point of view, during the first years of life, the emphasis must be placed on the growth and development of these children. Their condition makes them particularly prone to recurrent urinary tract infections, so their growth and nutrition must be carefully monitored, both clinically and paraclinically through regular renal ultrasound scans.

The prognosis is variable and depends on the severity of the structural defects. Mortality in developing country series is very high, due to a combination of renal, pulmonary and cardiac complications [9,21]. According to several authors, patient survival also depends on the optimal management and level of advancement of pediatric surgery, and thus of pediatric health care in general [9, 13]. In other words, survival of OEIS patients would be an indicator of the quality of pediatric care. In developing countries such as ours, the prognosis remains guarded, especially concerning the postoperative follow-up marked with anal and urinary incontinence [22].

Conclusion

The OEIS complex, although rare, represents a diagnostic and therapeutic challenge, especially in countries with limited resource setting. Its management requires a multidisciplinary consultation, involving curative and preventive aspects. However, given the social drama to which congenital birth defects are identified, the

popularization of genetic counselling, efficient prenatal consultations, antenatal diagnosis and surgical intervention are of growing necessity.

References

1. Varygin V, Bernotas Š, Gurskas P, Karmanovas V, Strupas S, Zimanaitė O, et al. Cloacalexstrophy: a case report and literature review. *Med Kaunas Lith.* 2011;47(12):682-5.
2. Gbenou AS, Assan BR, Akodjenou J, Enianloko NT, Yasségoungbé MG, Fiogbe MA. Oeis Syndrome (Cloacal Exstrophy): About Two Cases Treated at the Mother and Child Teaching Hospital in Cotonou (Benin). *Open J Pediatr.* 2020;10(03):535-41.
3. Woo LL, Thomas JC, Brock JW. Cloacal exstrophy: a comprehensive review of an uncommon problem. *J Pediatr Urol.* 2010;6(2):102-11.
4. Manassero-Morales G, Franco-Bustamante K, Matos-Rojas I. OEIS Complex, A Case Report. *J Intensive Crit Care.* 2016;2(1).
5. Arteaga-Vázquez J, Luna-Munoz L, Morales-Suarez JJ, Mutchinick OM. OEIS complex: Prevalence, clinical, and epidemiologic findings in a multicenter Mexican birth defects surveillance program. *Birth Defects Res.* 2019;111(11).
6. Crespo Rodríguez M, Vila Homs L, Campos Candela RJ, Simón Salvador CM, Garrido Palmer C, Ruiz de Gopegui R, et al. Cloacal exstrophy, a rare fetal malformation with difficult prenatal sonographic diagnosis: two case reports. *Med Balear.* 2020;35(3):43-7.
7. Varygin V, Bernotas Š, Gurskas P, Karmanovas V, Strupas S, Zimanaitė O, et al. Cloacal exstrophy: a case report and literature review. *Med Kaunas Lith.* 2011;47(12):682-5.
8. Saini R, Saini P, Saini L, Sehra R. omphalocele, exstrophy cloacae, imperforate anus, and spinal defects complex with absent foot. *Indian J Case Rep.* 2018;4:78-9.
9. Gbenou AS, Assan BR, Akodjenou J, Enianloko NT, Yasségoungbé MG, Fiogbe MA. Oeis Syndrome (Cloacal Exstrophy): About Two Cases Treated at the Mother and Child Teaching Hospital in Cotonou (Benin). *Open J Pediatr.* 2020;10(03):535-41.
10. Diamond DA, Jeffs RD. Cloacal exstrophy: a 22-year experience. *J Urol.* 1985;133(5):779-82.
11. Boyadjiev SA, Dodson JL, Radford CL, Ashrafi GH, Beaty TH, Mathews RI, et al. Clinical and molecular characterization of the bladder exstrophy-epispadias complex: analysis of 232 families. *BJU Int.* 2004;94(9):1337-43.
12. Lubala TK, Shongo MY, Mbuyi SM, Mutombo AM, Ngwej DT, Kabange FN. OEIS Complex (omphalocele-exstrophy of the bladder-anal imperforation-spina bifida) and prenatal alcohol exposure: a case report. *Pan Afr Med J.* 2013;15:142.
13. Mallikarjunappa B, Ghosh A. OEIS complex: A rare case report with review of literature. *J Ind Med Sci Acad.* 2014;27:24-5.
14. Ambike D, Byale A, Sayyad R, Rathod V, Bijarniya K. A Rare Case of Omphalocele, Exstrophy of Bladder, Imperforate Anus and Spinal Defect Complex with Genital Anomalies in a Term Neonate. *Pediatr Oncall J.* 2021;18(3)

15. Woo LL, Thomas JC, Brocke JW. Cloacal exstrophy: A comprehensive review of an uncommon problem. *J Pediatr Urol.* 2010;6:102-111.
16. Georges Pius K M, Aurore Albane E, Marie-Paul B, Komba D, Ngando VK, Eteme A et al. Neonatal Sepsis: Highlights and Controversies. *J Pediatr Neonatal.* 2022; 4(1): 1-5.
17. Chiabi A, Kago DA, Moyo GPK, Obadeyi B. "Relevance and Applicability of the Apgar Score in Current Clinical Practice". *EC Paediatrics* 2019;8(11):01-07. Doi: 10.33425/2689-1085.1035
18. Moyo GPK, Tetsiguia JRM. Discussing the "First Cry" as an Initial Assessment for Neonates. *Am J of Pediatr.* 2020;6(2): 129-132. doi: 10.11648/j.ajp.20200602.22
19. Källén K, Castilla EE, Robert E, Mastroiacovo P, Källén B. OEIS complex--a population study. *Am J Med Genet.* 2000;92(1):62-8.
20. Sowmya M, Shwetha S. Oeis Complex: a rare Case Report. *Int J Med Res Rev.* 2014;2(6):618-620.
21. Chou C-Y, Tseng Y-C, Lai T-H. Prenatal Diagnosis of Cloacal Exstrophy: A Case Report and Differential Diagnosis with a Simple Omphalocele. *J Med Ultrasound.* 1 mars 2015;23(1):52-5.
22. Crespo Rodríguez M, Vila Homs L, Campos Candela RJ, Simón Salvador CM, Garrido Palmer C, Ruiz de Gopegui R, et al. Cloacal exstrophy, a rare fetal malformation with difficult prenatal sonographic diagnosis: two case reports. *Med Balear.* 2020;35(3):43-7.
23. Ngwanou D H, Ngantchet E, Moyo GPK. Prune-Belly syndrome, a rare case presentation in neonatology: about one case in Yaounde, Cameroon. *Pan Afr Med J.* 2020;36:120.
24. Moyo GPK, Nguedjam M, Miaffo L. Necrotizing Enterocolitis Complicating Sepsis in a Late Preterm Cameroonian Infant. *Am J Pediatr.* 2020;6(2):83-86. doi: 10.11648/j.ajp.20200602.12
25. Moyo GPK, Sobguemezing D, Adjifack HT. Neonatal Emergencies in Full-term Infants: A Seasonal Description in a Pediatric Referral Hospital of Yaoundé, Cameroon. *Am J Pediatr.* 2020;6(2): 87-90. doi: 10.11648/j.ajp.20200602.13
26. Moyo GPK, Djoda N. The Emotional Impact of Mode of Delivery in Cameroonian Mothers: Comparing Vaginal Delivery and Caesarean Section. *American Journal of Psychiatry and Neuroscience.* 2020;8(1): 22-25. doi: 10.11648/j.ajpn.20200801.15
27. Moyo GPK, Mendomo RM, Batibonack C, Mbang AT. Neonatal Determinants of Mothers' Affective Involvement in Newly Delivered Cameroonian Women. *Journal of Family Medicine and Health Care* 2020;6(2):125-128. doi: 10.11648/j.ajp.20200602.21
28. Moyo GPK. Perinatal and Childbirth as a Factor of Decompensation of Mental Illness: The Case of Depressive States in Newly Delivered Cameroonian Women *ABEB* 2020: 4(4). ID.000592. DOI: 10.33552/ABEB.2020.04.000592
29. Moyo GPK, Djoda N. Relationship Between the Baby Blues and Postpartum Depression: A Study Among Cameroonian Women. *American Journal of Psychiatry and Neuroscience* 2020; 8(1): 26-29. Doi: 10.11648/j.ajpn.20200801.16
30. Moyo GPK. Epidemio-clinical Profile of the Baby Blues in Cameroonian Women. *Journal of Family Medicine and Health Care.* 2020;6(1):20-23. doi: 10.11648/j.jfmhc.20200601.14
31. Foumane P, Olen JPK, Fouedjio JH, GPK Moyo, Nsahlai C, Mboudou E. Risk factors of maternity blues after caesarean section in Yaoundé, Cameroon: a case-control analysis *Int J Reprod Contracept Obstet Gynecol.* 2016 Dec;5(12):4424-4427.
32. Hermann ND. Moyo GPK. Neonatal Determinants of Inadequate Breastfeeding: A Survey among a Group of Neonate Infants in Yaounde, Cameroon. *Open Access Library Journal* (2020); 7: e6541. DOI: 10.4236/oalib.1106541
33. Hermann ND, Moyo GPK, Ejake L, Félicitée N, Evelyn M, Linda M. Determinants of Breastfeeding Initiation Among Newly Delivered Women in Yaounde, Cameroon: a Cross-Sectional Survey *Health Sci Dis* 2020; 21:20-24
34. Moyo GPK, Dany Hermann ND. Clinical Characteristics of a Group of Cameroonian Neonates with Delayed Breastfeeding Initiation. *Am J Pediatr* 2020;6(3):292-295. doi: 10.11648/j.ajp.20200603.28
35. Moyo GPK, Hermann ND. The Psycho-Sociocultural Considerations of Breastfeeding in a Group of Cameroonian Women with Inadequate Practices. *J Psychiatry Psychiatric Disord* 2020; 4 (3): 130-138. doi: 10.26502/jppd.2572-519X0100
36. Moyo GPK, Ngwanou DH, Sap SNU, Nguetack F, Mah EM. The Pattern of Breastfeeding among a Group of Neonates in Yaoundé, Cameroon. *International Journal of Progressive Sciences and Technologies* 2020;22(1):61-66