

Coccidioidomycosis Meningitis in An Immunocompetent Worker: A Case Report

Rashmi R Bhuyan, MD*

Pathology department. Harbor-University of California Los Angeles Medical Center, USA.

***Corresponding author:** Rashmi R Bhuyan, Pathology department. Harbor-University of California Los Angeles Medical Center, USA. Email: RBhuyan@dhs.lacounty.gov

Citation: Bhuyan RR (2021) Coccidioidomycosis Meningitis in An Immunocompetent Worker: A Case Report. Annal Cas Rep Rev: ACRR-219.

Received Date: 08 April 2021; **Accepted Date:** 20 April 2021; **Published Date:** 27 April 2021

Abstract

“If you work in the dry dust of Arizona or California central valley
Surely be warned about fever, or deadly head-aches from all those Cocci!!”

Introduction

While pulmonary coccidiomycosis infections in the endemic places are seen very often, especially among immunocompromised people, CNS coccidiomycosis infection from environmental exposure in immunocompetent individual is not that common, but when it happens it is fatal. Risk is very high in certain occupations in endemic regions and the diagnosis may be challenging in absence of high clinical suspicions. Here, we report a case of coccidiomycosis meningitis in an immunocompetent individual, who went to Arizona for a week for his painting job. The purpose of this paper is to prevent the occupation-related dreaded incidence of fungal brain infection in endemic places with robust public health measures.

Case presentation

48 years old male with past medical history of hypertension, hyperlipidemia and prediabetes, admitted for acute on chronic severe headache of three months. History elicited included recent travel to Arizona for several weeks for painting job a month before the symptoms appeared. He visited the emergency department five times in two months with complains of chronic head-aches and photophobia, was sent back home four times with presumptive diagnosis of migraine due to benign-looking head-aches in absence of focal neurological symptoms accompanied by non-specific imaging findings. Towards the end of three months of having progressively increasing head-aches associated with photophobia, he was sent to the emergency department by his primary care provider, requesting to evaluate for possible meningitis. This was patient’s fifth time visit to the emergency department and, at that point, he was found to have increased confusion and sixth nerve palsy suggesting increased intracranial pressure. During this visit, his mental status was sleepy, arousable only to name. His CT thorax showed 3 mm and 4 mm nodules in right lower lobe of lung (Fig. 1).

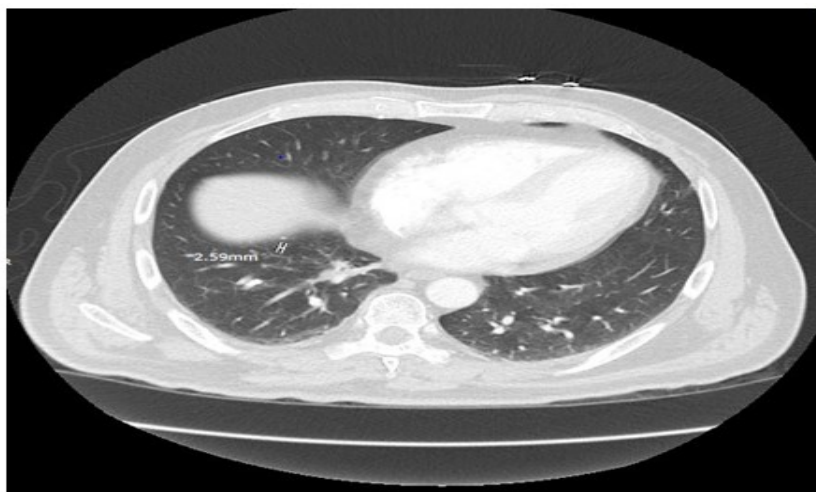


Figure 1: CT thorax showing a 4 mm and 3 mm pulmonary nodule at right lower lobe.

Non-contrast CT head showed acute communicating hydrocephalus (Fig. 2) and MRI head confirmed the CT findings showing diffuse leptomeningeal enhancement around basal cisterns and scattered enhancing foci with differential diagnosis of meningitis, neuro-sarcoidosis, and leptomeningeal carcinomatosis with a strong suspicion for tubercular meningitis due to thick basal cisternal distribution. Patient was placed on empirical treatment with rifampicin for tubercular meningitis. Then, lumbar puncture was performed that showed pattern consistent with infectious fungal or tubercular etiology with increased protein, decreased glucose, and increased WBC with

elevated lymphocytes with negative Gram stain (Fig. 3). Culture of cerebrospinal fluid grew mold supporting a dimorphic fungus as the etiologic agent (Fig. 4). Both blood and Cerebrospinal fluid showed high titer of Coccidioidomycosis antibody, antibody for Histoplasma came negative. He was diagnosed with Coccidioidomycosis meningitis finally in January, approximately three months after his first complain of headaches that started in late November intermittently, later became constant with progressive mental decline in the last 2 weeks with associated symptoms of nausea, vomiting and dizziness.

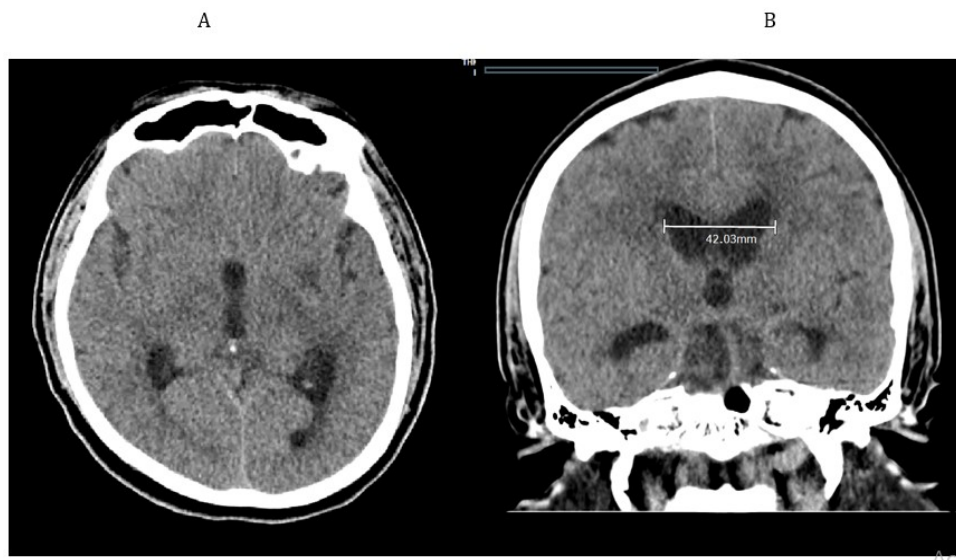


Figure 2 A and B: (1). Stable mild communicating hydrocephalus compared to prior CT, we see mild dilatation of lateral ventricles along with mild dilatation of peri-ventricular area head on 1/25/21 (2). Stable area of low attenuation within left lower basal ganglia, which likely represents a perivascular space versus chronic ischemic white matter lesion.

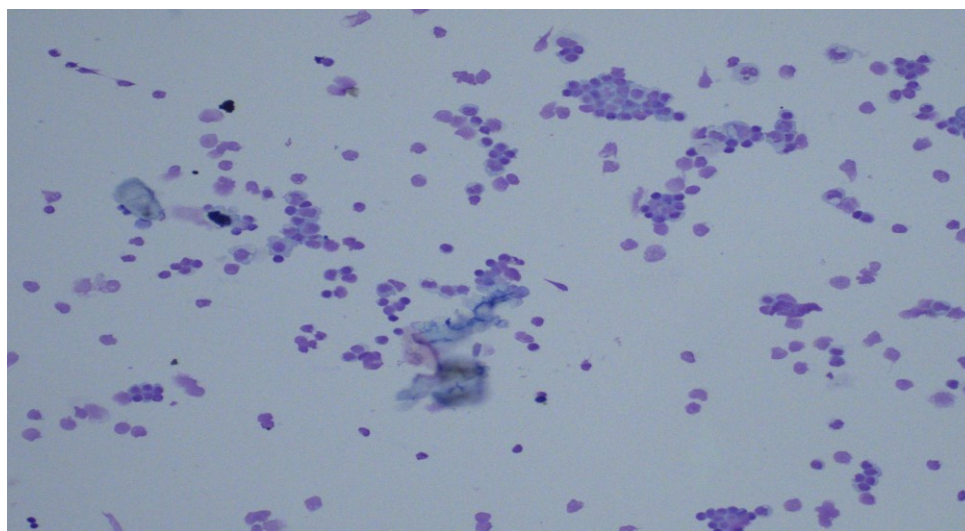


Figure 3: Cerebro-spinal fluid, Lumbar puncture: -reactive appearing lymphocyte, few neutrophils, and occasional monocyte.

Growth on BAP from CSF

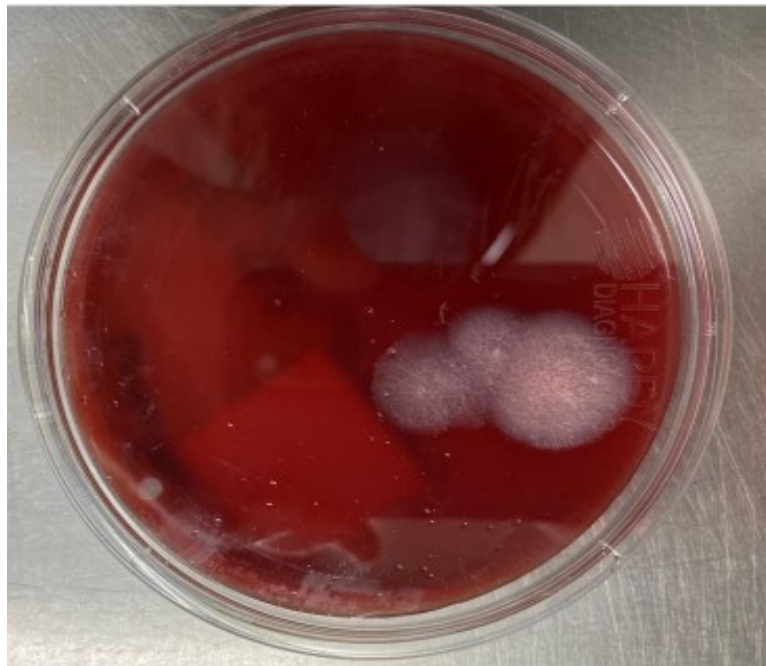

Figure 4: Growth on BAP from CSF, *Coccidioides immitis* identified on DNA probe.

Treatment

Patient was placed on fluconazole 1200 mg per oral, high dose recommended due to interaction with Rifampin which will persist for one week after rifampin stopped. Patient was initially put on Rifampicin for empirical treatment of tuberculosis meningitis. Patient will need lifelong treatment with fluconazole in this case. Patient's mental alertness showed gradual improvement 1 week after initiation of fluconazole treatment. He was discharged on 800 mg of fluconazole once a day, to be followed by the infectious disease team for further management.

Discussion

Coccidioides species are dimorphic fungi that cause disease in humans when arthroconidial spores are inhaled in the environment of endemic regions. *Coccidioides* spp. are endemic in the southwest region of the United States including Arizona and central California. Infection with *Coccidioidomycosis* spp. commonly remains asymptomatic, but oftentimes present as self-resolving pneumonia and, in certain cases, mostly with immunocompromised, life-threatening disseminated extra-pulmonary mycoses [1]. In rare instances, life-threatening disseminated mycoses can occur in immunocompetent healthy hosts in certain occupations that needs working outside getting exposed to dry, alkaline dusts in endemic regions. Primary infection occurs in the lung after inhalation of air-borne arthrospores [2]. The most deleterious extrapulmonary dissemination is the spread of *Coccidioides* spp. to the central nervous system causing meningitis [3]. CNS coccidioidomycosis occurs when coccidioidological spherules or endospores migrate to the meninges or into brain tissue. In an early

study of 35 autopsy cases, central nervous system coccidioidomycosis was noted to have a predilection for the basilar portion of the brain; pathologic finding observed were thickened, hyperemic meninges, endarteritis obliterans with inflammatory cells throughout the outer layers of small arteries and arterioles with focal necrosis, inflammatory exudates and infarcts, principally of the basal ganglia, thalamus, and white matter and thickened spinal cord meninges with granulomatous inflammation [4].

If coccidioidomycosis is suspected, several tests can be helpful. A complete blood count and differential may show eosinophilia or inflammatory markers such as ESR or CRP, and a chest X-ray may show any range of lobar consolidation, nodular infiltrate, lobar consolidation, nodular infiltrate, cavitation, and hilar or mediastinal lymphadenopathy. At the same time, as none of the aforementioned results are specific, culture and antibody testing are usually necessary. A positive culture for *Coccidioides* or direct visualization of the spores in any clinical specimen, such as a sputum sample or cerebrospinal fluid is definitive [5].

When left untreated, CM is uniformly fatal. Though the fatality has improved with the use of Amphotericin B and azoles, morbidity is still substantial due to complications from the disease, devices used for treatment management (eg. Ventricular shunt for hydrocephalus decompression) and side effects of medications as much higher doses are necessary for prolonged period of time. The gold standard of treatment now is fluconazole. Infectious Disease Society of America (IDSA) guidelines recommend lifelong 'azoles' therapy for CM as they are fungistatic agents with rates of relapse after discontinuation of therapy of nearly 80%.

Treatment dosing ranges from 400 to 1200 mg daily, but 800- 1200 mg daily is preferred given the lower risk of relapse [6].

Conclusion: Travel to endemic regions can result in the acquisition of Coccidiomycosis for both immunocompetent and immunosuppressed individuals. The morbidity and mortality of CM is devastating. So, strict public health measures required to protect the workers at risk of contracting this dreaded infection in the endemic regions.

Conflicts of interest

The author declares that there are no conflicts of interest.

Reference

1. Lang, R., Stokes, W., Lemaire, J., Johnson, & John, C. A Case Report of *Coccidioides posadasii* meningoencephalitis in an immunocompetent host (2019). <https://bmcinfectdis.biomedcentral.com/articles/10.1186/s12879-019-4329-0>
2. Lammering, C. J., Iv, M., Gupta, N., Pandit, R. Imaging Spectrum of CNS Coccidioidomycosis: Prevalence and Significance of Concurrent Brain and Spinal Disease. <https://www.ajronline.org/doi/10.2214/AJR.12.9264>
3. Jin, D. A Case report of an immune-competent patient with *Coccidioides* meningoencephalitis with atypical brain magnetic resonance imaging findings during a 1 year follow-up. *The Southwest respiratory and critical care chronicles* 2019; 7(28):33-37 <https://pulmonarychronicles.com/index.php/pulmonarychronicles/article/view/542/1183>
4. Jackson NR, Blair JE, Ampel NM. Central Nervous System Infections Due to Coccidioidomycosis. *J Fungi (Basel)*. 2019;5(3):54. Published 2019 Jun 28. doi:10.3390/jof5030054. <https://www.ncbi.nlm.nih.gov/pmc/articles/PMC6787616/>
5. Uptodate, n.d. <https://www.uptodate.com/contents/coccidioidal-meningitis#H1443498574>
6. <https://health.ucdavis.edu/valley-fever/about-valley-fever/clinical-manifestations/coccidioidal-meningitis/index.html>